

## Role of High Frequency Ultrasound in Evaluation of Palpable Breast Masses in Correlation with Conventional Mammography, Histopathology/Fine Needle Aspiration Cytology.

\*Paarthipan Natarajan<sup>1</sup>, Sureendhar Mohan<sup>2</sup>, Premkumar G<sup>3</sup>, Rajasekhar K. V.<sup>4</sup>

<sup>1</sup>Associate Professor, Department of Radiodiagnosis, Meenakshi Medical College Hospital and Research Institute(MMCH & RI). Kanchipuram.

<sup>2</sup>Assistant Professor, Department of Radiodiagnosis, Meenakshi Medical College Hospital and Research Institute(MMCH & RI). Kanchipuram.

<sup>3</sup>Post graduate student, Department of Radiodiagnosis, Meenakshi Medical College Hospital and Research Institute(MMCH & RI). Kanchipuram.

<sup>4</sup>Professor and HOD, Department of Radiodiagnosis, Meenakshi Medical College Hospital and Research Institute(MMCH & RI). Kanchipuram.

**Abstract:** Using high resolution Ultrasonography there are reliable signs to differentiate benign & malignant breast masses and select appropriate cases for mammography & HPE. Positive predictive value for biopsy can be increased by proper complete diagnostic work up in which sonomammography & conventional mammography is also included.

**Objective:** The purpose of our study was to characterize the palpable solid breast mass and categorizing each mass as benign and malignant using high frequency ultrasonogram and to correlate the benign and malignant breast mass with mammographic & tissue diagnosis.

**Materials and Methods:** This study was a prospective analysis which includes 50 female patients, of age ranging between 35–75 years with history of palpable breast mass. Data for the study was collected from the patients referred to Department of Radio diagnosis at Meenakshi Medical College and research institute Kanchipuram for the period of two years. A structured, pre-prepared case proforma (CP) was used to enter the clinical history, physical examination findings, investigations-sonomammography, conventional mammography and histopathology/FNAC findings. Later the conventional mammography findings and tissue diagnosis results were correlated with sonological findings by statistical analysis.

**Results:** The US findings most predictive for a malignant tissue diagnosis were poorly defined/ spiculated or microlobulated margins, irregular shape, not oriented parallel to skin, taller than longer, > 3 lobulations and width-to-AP dimension ratio of 1.4 or less. The findings most predictive for a benign tissue diagnosis were oval or round shape, circumscribed margins, orientation parallel to skin, < 3 lobulations / microlobulations and width-to-AP dimension ratio greater than 1.4.

**Conclusion:** Ultrasound features for differentiating benign from malignant solid masses have the potential to help to avoid radiation exposure & decrease the number of biopsies performed for benign solid masses.

**Keywords:** Sonomammography; benign breast mass; malignant breast mass; BIRADS.

### I. Introduction

Detection of breast cancer in its earliest possible stage is the ultimate goal in imaging the breast and radiologist plays an important role in this place. Radiological imaging chiefly includes, USG (ultrasonography) and MG (mammography) followed by tissue biopsy. The mortality of breast cancer can be reduced by the routine screening of healthy women with USG. This is due to changes in the breast like distortion of fibro glandular architecture, asymmetry, neodensity, and micro calcifications which are picked up earlier than lesions that become clinically palpable, or are sometimes detected by self-examination.

Ultrasonogram plays a major part in differentiating solid and cystic masses. It is useful in the evaluation of palpable masses not visible in radio graphically dense breast, abscesses, masses that are not completely evaluable with MG and in young patients susceptible to radiation damage. Both USG and MG methods have been used in attempts to reduce the negative to positive biopsy ratio. The sonographic evaluation of a palpable breast mass is based on three categories. First, for a simple cyst, no additional workup is required, although aspiration can be performed if desired by the patient or physician. Second, for a palpable solid mass or complex cyst, further intervention is often required, such as fine-needle aspiration or core cut biopsy. Third, if findings from the sonography are negative (no discrete cystic or solid lesions are seen to correlate with the palpable mass) and the findings from the mammography are negative, then the management of the palpable mass is based on the results of the physical examination.

The large number of biopsies performed for benign breast abnormalities has been considered as a severe problem. Excessive biopsies for benign lesions have adverse effects on society and on the women who go through them by rising the costs of screening projects, causing morbidity, and adding to the barriers that keep women from using a potentially lifesaving procedure<sup>[1, 2, 3]</sup>.

Therefore, Ultrasonography (US) helps to increase the positive predictive value for biopsy (biopsy yield of cancer) by performing a complete diagnostic work-up. For a palpable lesion, characterization of lesion is important in further management of the problem. Improvements in US equipment have prompted more recent studies with findings that describe reliable signs for differentiating benign from malignant masses. We conducted a prospective analysis of 50 consecutive cases in which patients presented palpable breast masses and underwent breast US followed by correlation with mammographic & tissue diagnosis.

## **II. Objective**

This study was carried out,

1. To characterize the palpable solid breast mass and categorizing each mass as benign and malignant using high frequency ultra sonogram.
2. To correlate the benign and malignant breast mass with mammographic & tissue diagnosis.

## **III. Materials And Methods**

This study was a prospective analysis which includes 50 female patients, of age ranging between 35–75 years with history of palpable breast mass. Data for the study was collected from the patients referred to Department of Radio diagnosis at Meenakshi Medical College and research institute Kanchipuram from January 2014 to September 2015.

### **Inclusion criteria**

All female patients with palpable solid breast lesions based on sonological findings and within age group between 35 - 75 years.

### **Exclusion criteria**

All female patients with palpable cystic breast lesions based on sonological findings and outside the age group between 22-75 years.

### **Technique of sonomammography**

In this study all US examinations were performed with a 7-10-MHz high frequency linear-array of VOLUSON S6-PRO model.

### **Technique of conventional mammography**

MAMMOMAT model was used to obtain all the images of breast lesions for females who come under our inclusion criteria. Images were taken in both cranio-caudal and medial lateral oblique views.

### **Patients scanning technique:**

Before the ultrasound examination a detailed clinical history and clinical examination was performed. Patients were examined in supine position.

### **Technique of USG guided FNAC:**

After explaining the procedure, the patient was made to lie on a bed and the lump was palpated. The skin over the lump was cleaned with spirit. The high linear probe was placed over the mass and under sonographic guidance the needle was inserted into the lesion after informing the patient about it. After the insertion, rapid back and firm strokes of the needle were made within the lesion. In most cases, non-aspiration technique was used. In those cases where aspiration was applied, a syringe was attached to the needle for creating negative pressure and before withdrawing the needle, the negative pressure was released. The material in the needle was expressed on clean slides and smeared using another clean slide

### **Sono-mammographic observations:**

A thorough ultrasound examination was performed in sagittal plane, transverse plane and radial scanning.

### **The following observations were made:**

1. Shape (oval, round, lobulated, or irregular),
2. Margins (circumscribed, ill defined, spiculated, or microlobulated),
3. Width-to-anteroposterior (AP) dimension ratio,

4. Posterior echoes (enhanced, unaffected, or decreased), Intensity of the beam posterior to lesion was noted and was reported as posterior enhancement if the intensity of the beam was increased behind lesion. Reported as shadowing when the intensity reduced.
5. Echogenicity (intensity of internal echoes), Reflectivity of the lesion were compared with fibroglandular tissue and was reported as hypoechoic if the lesion was less reflective than surrounding tissue, anechoic when clear and hyperechoic when echogenicity more than surrounding tissue.
6. Echotexture (homogeneity of internal echoes),
7. Presence of calcifications,
8. Presence of pseudocapsule
8. Edge rarefaction

### Conventional Mammographic Technique

Both screening and diagnostic mammograms routinely start with the standard medio-lateral oblique and cranio-caudal projections. For further evaluation of suspected abnormalities supplemental views including exaggerated cranio-caudal, spot compression, magnification, vertical lateral, tangential, and push-back views may be obtained.

A structured, pre-prepared case proforma (CP) was used to enter the clinical history, physical examination findings, investigations-sonomammography, conventional mammography and histopathology/FNAC findings. Later the conventional mammography findings and tissue diagnosis results were correlated with sonological findings by statistical analysis.

## IV. Results

**Table 1: Association of US Features with Malignant versus Benign Tissue diagnosis**

US / Mammography features	Number of patients	Tissue Diagnosis		P value
		Malignant	Benign	
<b>Shape</b>				
Round/Oval	22 (44.0)	1 (4.5)	21(95.5)	0.004*
>3 lobulations	9(18.0)	3(33.3)	6(66.7)	*
Three or fewer lobulations	9(18.0)	2 (11.1)	7(77.7)	0.668
Irregular	10(20.0)	6(60.0)	4(40.0)	1.000
				0.007*
				*
<b>Margins</b>				
Circumscribed	32(64.0)	2(6.3)	30 (93.8)	<0.001
Ill defined	14(28.0)	7(50.0)	7(50.0)	**
Microlobulated	3(6.0)	2(66.7)	1(33.3)	0.023*
Speculated	1(2.0)	1 (100.0)		0.139
				0.240
<b>Width of AP dimension ratio</b>				
≤ 1.4	21(42.0)	8(38.1)	13(61.9)	0.047*
>1.4	29(38.0)	4 (13.8)	25(86.2)	0.047*
<b>Echotexture</b>				
Heterogeneous	13(26.0)	4(30.8)	9(69.2)	0.506
Intermediate	8(16.0)	3(37.5)	5(62.5)	0.379
Homogenous	29(58.0)	5(17.2)	24(82.8)	0.189
<b>Echogenicity</b>				
Hyper echoic	1(2.0)	0	1(100.0)	1.000
Iso echoic	23(46.0)	4 (17.4)	19(82.6)	0.313
Hypo echoic	26(52.0)	8(30.8)	18(69.2)	0.243
<b>Posterior Echo Intensity</b>				
Enhanced	20(40.0)	4(20.0)	16(80.0)	0.740
Unaffected	23(46.0)	6(26.1)	17(73.9)	0.750
Attenuated	7(14.0)	2 (28.6)	5(71.4)	1.000
<b>Pseudo capsule</b>				
Present	19 (38.0)	2 (10.5)	17(89.5)	0.100
Absent	31(62.0)	10(32.3)	21(67.7)	0.100
<b>Edge refraction</b>				
Present	18 (36.0)	2(11.1)	16(88.9)	0.170
Absent	32 (64.0)	10(31.3)	22(68.8)	0.109
<b>Calcifications</b>				
Present	3 (6.0)	ND	ND	-
Absent	47 (94.0)	ND	ND	-

Significant figures

+ Suggestive significance  $0.05 < P < 0.10$

\* Moderately significant  $0.01 < P \leq 0.05$

\*\* Strongly significant  $P \leq 0.01$

Table 4 shows the frequency of specific US features and the correlation between these specific features and the tissue diagnosis (benign vs. malignant). The US features most predictive of a benign tissue diagnosis were oval or round shape, circumscribed margins, presence of edge refraction, and width-to-AP dimension ratio greater than 1.4. The features most predictive of a malignant tissue diagnosis were spiculated or Microlobulated margins, irregular shape, ill-defined margins, and width-to-AP dimension ratio of 1.4 or less.

**Table 2:** Correlation of shape of the masses with tissue diagnosed benign and malignant masses

SHAPE	BENIGN	MALIGNANT
RO/OV	4.5	95.5
<3	11.1	77.7
>3	33.3	66.7
IR	60	40

**Table 3:** Correlation of margins of the masses with tissue diagnosed benign and malignant masses

MARGIN	BENIGN	MALIGNANT
Circumscribed	6.3	93.8
Microlobulated	66.7	33.3
Ill defined	50	50
Speculated	100	0

**Table 4:** Correlation of AP dimensions of the masses with tissue diagnosed benign and malignant masses

Width/AP	>1.4	<1.4
BENIGN	13.8	38.1
MALIGNANT	86.2	61.9

**Table 5:** Correlation of posterior echo intensity of the masses with tissue diagnosed benign and malignant masses

Posterior Echo Intensity	BENIGN	MALIGNANT
Enhanced	20	80
Unaffected	26.1	73.9
Attenuated	28.6	71.4

Some features were not reliable in differentiating between benign and malignant lesions. For example, the effects of masses on posterior echo intensity were not a useful determinant. Some features that showed excellent correlation with a benign or malignant tissue diagnosis were too infrequent to be generally applicable. For example, a hyperechoic lesion was very reliable as a predictor of benignity but was reported in only 2% of the masses.

## V. Discussion

Breast cancer is one of the most prevalent cancers in the world among women. Breast masses are common and usually benign, but effective evaluation and prompt diagnosis can rule out malignancy. Breast masses are common in female and amongst all the breast masses, malignant masses are the most feared. Breast cancer is the commonest cause of cancer mortality in females whereas breast cancer in men accounts for only 0.7% of all breast cancers.

Ultrasonogram is perfect modality for characterizing breast masses & are easily available, relatively cheaper and can take relatively less time when compared to other imaging techniques. The role of high frequency ultra sound in breast imaging has evolved over the years. Previously US for breast imaging has been restricted to differentiation of cysts versus solid masses. But now US for breast imaging also play an important role in guiding interventional procedures such as needle aspiration, core-needle biopsy, and prebiopsy needle localization. Screening US has also been advocated for the dense breast. Our study investigates the general applicability of high frequency US features in differentiating benign from malignant solid breast masses.

The specific sonographic features determining the benign nature of the lesion include intense hyper echogenicity, ellipsoid shape, gentle lobulations, thin echogenic pseudo capsule and less than three gentle lobulations. Malignant nature of the lesion is given by spiculations, angular margins, shadowing, microlobulations and micro calcifications. Though a definitive diagnosis is possible with noninvasive imaging procedure such as sonography, for most lesions mammography or histopathology or cytology (biopsy/FNAC)

are proven tools and essential for obtaining confirm diagnosis. The mammographic features of the breast mass help in diagnosis. Benign lesions show round to oval shape, well defined margins, few lobulations, low soft tissue density and fat containing lesions. Malignant lesions are high soft tissue density, irregular margins, multiple lobulations and spiculations with or without micro calcifications. So in our study we have used these tools to correlate the diagnosis obtained using US in evaluation of palpable breast masses and to characterize them as benign / malignant.

Many studies in the past have described specific US findings to determine if a solid mass is benign or malignant. Shape, margins, and echogenicity are the three main features that are usually analyzed in the evaluating of masses. Stavros et al has renewed interest in the potential value of these US diagnostic criteria<sup>[4]</sup>. However, in the latter investigation, one highly experienced radiologist obtained and interpreted the images, so the accuracy might not be reproducible in general practice. The data of Murad M, Bari V et al confirms that certain ultrasound features can help differentiate benign from malignant masses<sup>[5]</sup>. Features that characterized masses as benign include circumscribed margins and a width to antero-posterior (AP) dimension ratio greater than 1.4. Features that characterized masses as malignant include irregular shape, spiculated margins and width to antero-posterior (AP) dimension ratio of 1.4 or less. Certain features such as posterior echoes were not reliable for differentiating benign from malignant masses. The least useful US features in our study were echogenicity, presence of pseudo capsule, posterior echo intensity, presence of calcifications, and echo texture. Al-Dabbagh AA, Al-Baghdadi TM in 1996 evaluated sonographic features of malignant breast masses in which 114 patients (age 23-75 years) with breast masses were studied and 107 of them were suspected to have malignancy using wall contour, echogenicity, echo pattern, posterior-attenuating shadow and lesion length-to-width ratio as his criteria<sup>[6]</sup>. Using these features, the positive detection rate for malignancy was 91.2%. In conclusion, sonographic diagnosis of breast malignancies can be used in the assessment of breast masses. In our study out of 50 patients 12 patients were proved to be malignant showing the positive percentage of more 75 % with irregular shape & more than 50% of the patient with illdefined / spiculated margins showed positive for malignancy.

Tavassoli K, Cavalla P, Porcelli A, Surico N also evaluated sonographic features of breast masses in 1997 using Kasumi-Kamio parameters (margins, peripheral echoes, internal echoes, posterior echoes, lateral shadow cones) and the ratio between the longitudinal and transverse diameter of the breast lump form the basis for a list of standardised diagnostic criteria on which to base an analysis of breast disease that assesses the specificity and sensitivity of ultrasonography as a valid, reliable initial step in the diagnosis of breast tumours. The study was based on a series of 129 tumour cases and produced correct diagnosis in 89.28% of benign, 83.33% of malignant cases.

As described in the literature we identified that 3 best features met the criteria of frequency and reliability. These three features were the shape, margins, and width-to-AP dimension ratio of the mass. It is important to emphasize that the criteria for differentiating benign from malignant solid masses should be strictly applied, as emphasized by Stavros et al. So these characteristics could be strictly applied to predict a diagnosis of benignity. In our analysis of the data showed that use of these three features alone, to identify masses that did not require biopsy could have improved the overall positive predictive value (biopsy yield of carcinoma) by 16% (from 23% to 39%).

Weinstein SP et al in 2004 studied that Although posterior acoustic shadowing is a sonographic feature that is most commonly associated with mammary malignancies, this sonographic finding may also be seen with benign breast lesions, which also correlated with study where posterior acoustic shadowing is also seen in benign mass lesions<sup>[7]</sup>.

Skaane P, Engedal K in 1998 Analyzed the sonographic features in the differentiation of fibroadenoma and invasive ductal carcinoma in which Irregular shape and contour, extensive hypoechogenicity, shadowing, echogenic halo, and distortion of surrounding tissue were the findings with the highest predictive value of malignancy. Our study showed a positive predictive value of more than 75% using these criteria for differentiating benign & malignant masses. A thin echogenic pseudocapsule was the most important sonographic finding predictive of the benign nature of a solid mass, this criteria in our study showed 89.5 % of patients having mass with pseudo capsule were proved to be benign. Echo texture was of little value in the differentiation of breast tumors.

Another study done by Chen SC et al in 2003 showed that the accuracy of breast sonography in differentiating between benign and malignant tumors < or = 1, 1.1-2 and > 2 cm in size was 75.6%, 86.4% and 88.4%, respectively<sup>[8]</sup>. This criteria in our study is more or less equal to the study done by chen et al, we took sizes >1.4 cms and < 1.4 cms which showed a positive predictive value of 86.2% & 61.9 cms for benign masses. On multiple regression analysis, margin was the only significant factor for tumors < or = 1 cm. Using margin as an important criteria in our study, the difference between benign and malignant lesions are easily made. Lesions with Circumscribed margins where proved to be mostly benign where as illdefined or spiculated margins has a possibility of 50% of being either benign or malignant.

Lamb PM et al in 2000 demonstrated classical appearance of a malignant breast mass as a spiculated mass on mammogram associated with acoustic shadowing on ultrasound is more typical of a low-grade tumor<sup>[9]</sup>. In comparison, high-grade tumors are more likely to demonstrate posterior acoustic enhancement, and a proportion has a well-defined margin on ultrasound. Therefore, high-grade invasive ductal carcinoma may paradoxically display similar imaging features to a benign breast mass which very well correlated with our study where speculated margins are seen in 90% of malignant cases & posterior echo intensity cannot be considered as an important factor in differentiating benign and malignant masses as enhanced posterior echoes are seen in both malignant & benign masses.

In women younger than 30 years, in whom mammography is less useful, US is often considered the modality of choice to initiate the evaluation of a palpable mass. In our study, the younger women who underwent US but not mammography would have benefited the most from the application of US criteria for benign versus malignant solid masses. Use of the diagnostic criteria would have eliminated the need for biopsies in the women who did not have mammograms.

When assessing the general usefulness of these US diagnostic criteria as a method of avoiding unnecessary radiation exposure in mammography & unnecessary excisional biopsy. It is also important to remember that there are other options for determining whether a solid mass is benign or malignant. For example, fine-needle aspiration biopsy with cytological analysis is a relatively inexpensive, minimally invasive procedure that many experienced radiologists find useful in the evaluation of solid masses. Core-needle biopsy is now widely used for the evaluation of non palpable solid masses and is readily adaptable to US guidance.

## **VI. Conclusion**

The US features in our study most predictive of a benign tissue diagnosis were oval or round shape, circumscribed margins, presence of edge refraction, and width-to-AP dimension ratio greater than 1.4. The features most predictive of a malignant tissue diagnosis were spiculated or microlobulated margins, irregular shape, ill-defined margins, and width- to- AP dimension ratio of 1.4 or less. Some features were not reliable in differentiating between benign and malignant lesions. For example, the effects of masses on posterior echo intensity were not a useful determinant. Some features that showed excellent correlation with a benign or malignant tissue diagnosis were too infrequent to be generally applicable. The results of our study were encouraging in that we were able to identify the most applicable US features for differentiating benign from malignant solid masses. These features have the potential to help decrease the number of biopsies performed for benign solid masses.

Finally, the results of our study were encouraging in that we were able to identify the most applicable US features for differentiating benign from malignant solid masses. These features have the potential to help us to decrease the need for radiation exposure on mammography & the number of biopsies performed for benign solid masses.

## **References**

- [1]. Fields SI. Ultrasound Mammographic-histopatologic correlation. *Ultrasound imaging* 1980; 2:150-161.
- [2]. Harmine M, Zonderland, MD, Emile G, Coerkamp, MD, Jo Hermans, PhD, Marc J. van de Vijver, MD, PhD and Ad E. van Voorthuisen, MD, PhD) *Diagnosis of Breast Cancer: Contribution of US as an Adjunct to Mammography*. *Radiology*. 1999; 213:413-422.
- [3]. Miller AB. The costs and benefits of breast cancer screening. *Am J Prev Med* 1993; 9:175-180.
- [4]. Stavros AT, Thickman D, Rapp CL, Dennis MA, Parker SH, Sisney GA. Solid breast nodules: use of sonography to distinguish between benign and malignant lesions. *Radiology* 1995; 196:123-134.
- [5]. Murad M, Bari V. Ultrasound differentiation of benign versus malignant solid breast masses. *J Coll Physicians Surg Pak*. 2004 Mar;14(3):166-9.
- [6]. Al-Dabbagh AA<sup>1</sup>, Al-Baghdadi TM. Evaluation of the sonographic features of malignant breast masses. *Ann Saudi Med*. 1996 Mar;16(2):119-22.
- [7]. Weinstein SP<sup>1</sup>, Conant EF, Mies C, Acs G, Lee S, Sehgal C. Posterior acoustic shadowing in benign breast lesions: sonographic-pathologic correlation. *J Ultrasound Med*. 2004 Jan;23(1):73-83.
- [8]. Chen SC, Cheung YC, Su CH, Chen MF, Hwang TL, Hsueh S. Analysis of sonographic features for the differentiation of benign and malignant breast tumors of different sizes. *Ultrasound Obstet Gynecol*. 2004 Feb;23(2):188-93.
- [9]. Lamb PM<sup>1</sup>, Perry NM, Vinnicombe SJ, Wells CA. Correlation between ultrasound characteristics, mammographic findings and histological grade in patients with invasive ductal carcinoma of the breast. *Clin Radiol*. 2000 Jan;55(1):40-4.

## VII. Figures

Figure: 1

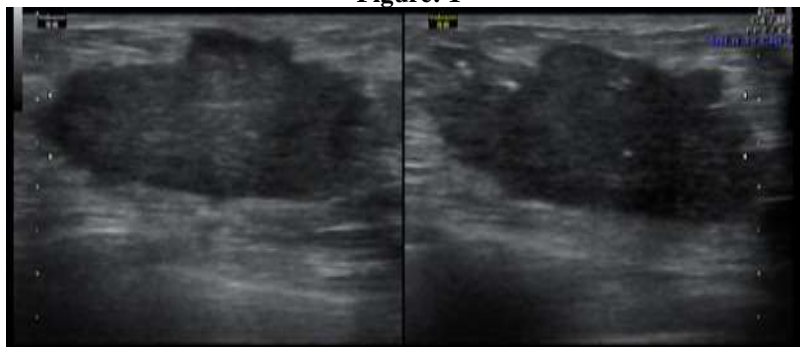

Figure - 1: Well - Defined Hypoechoic malignant Mass Lesion With Irregular Margins And Posterior Acoustic Shadowing.

Figure: 2

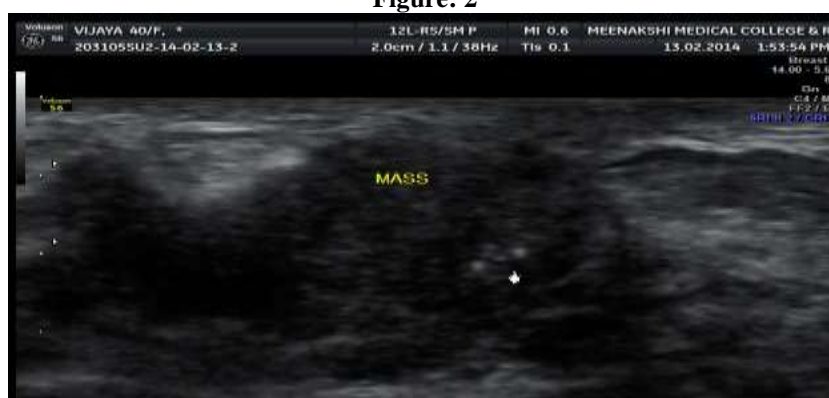

Figure – 2: Well - Defined Hypoechoic malignant Mass Lesion With Irregular Margins And Few Tiny Specks Of Microcalcification.

Figure: 3

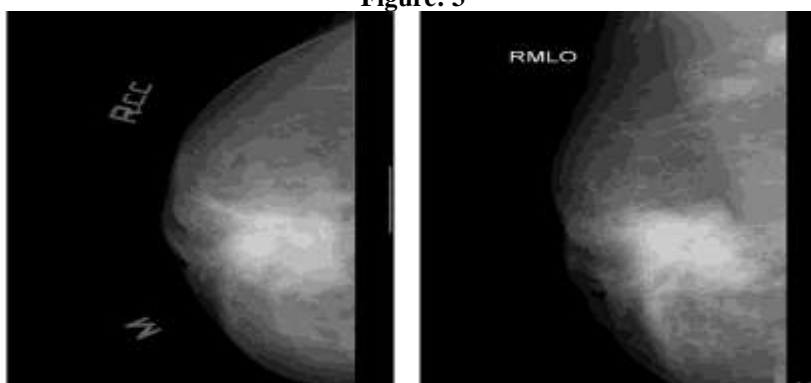
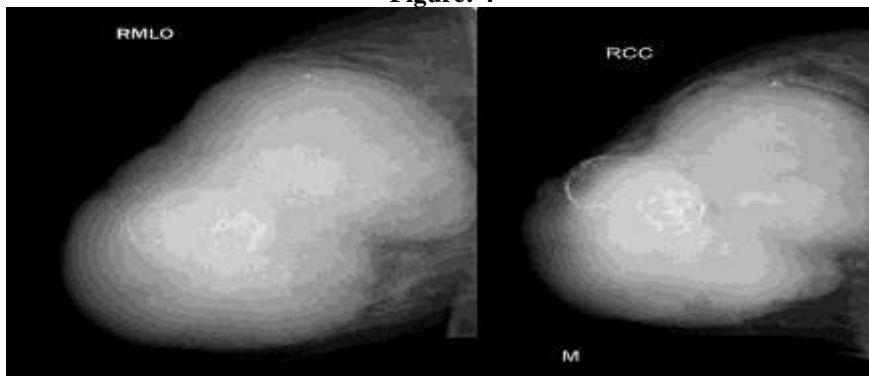


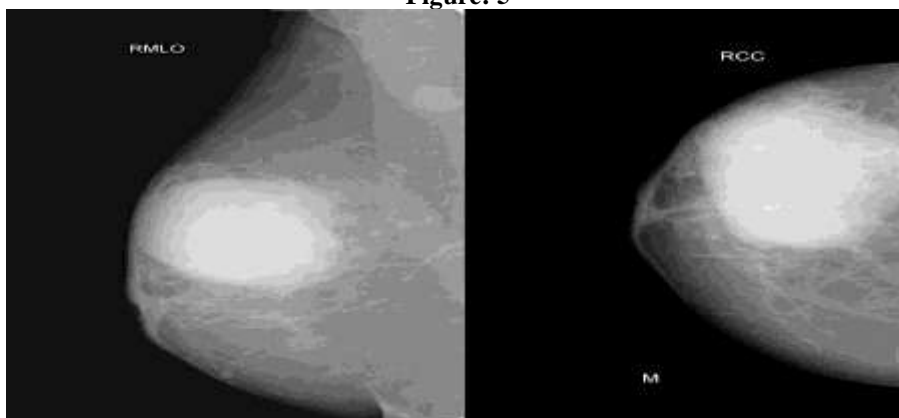
Figure – 3: Mammogram Of Right Breast – CC AND MLO Views Shows An Illdefined Focal Lesion With Spiculations And Surrounding Architectural Distortion In Retro Areolar Region.

**Figure: 4**



**Figure – 4:** Mammogram Of Right Breast – CC AND MLO Views Show A Large, Multi Lobulated Mass Lesion Showing Thin Amorphous Curvilinear Calcifications

**Figure: 5**



**Figure – 5:** Mammogram Of Right Breast-MLO AND CC Views Show A Well- Defined Homogenous Density Mass In Supero-Lateral Quadrant With Overlying Skin Thickening. An Axillary Lymph Node Is Also Noted.